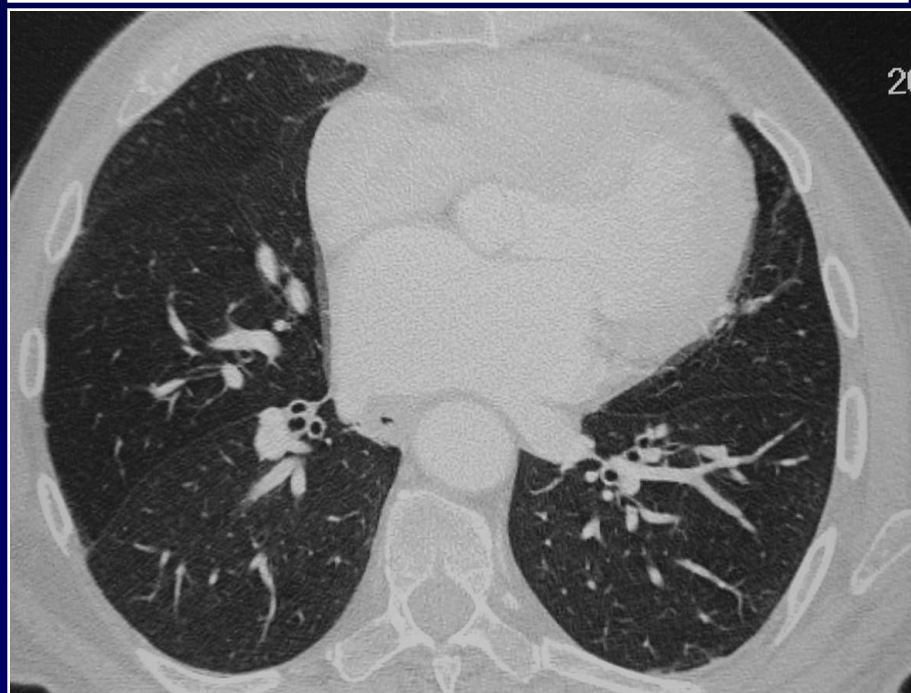
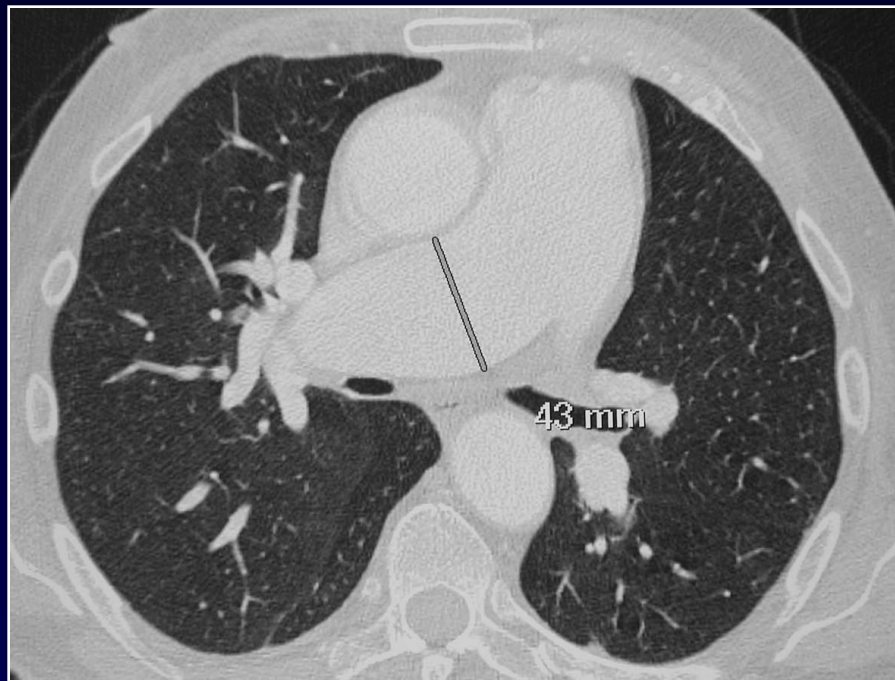


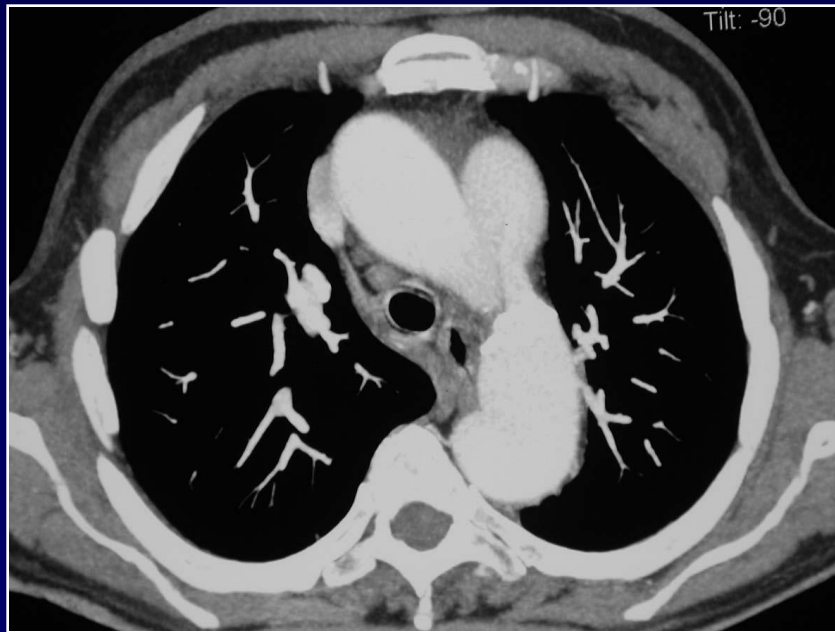
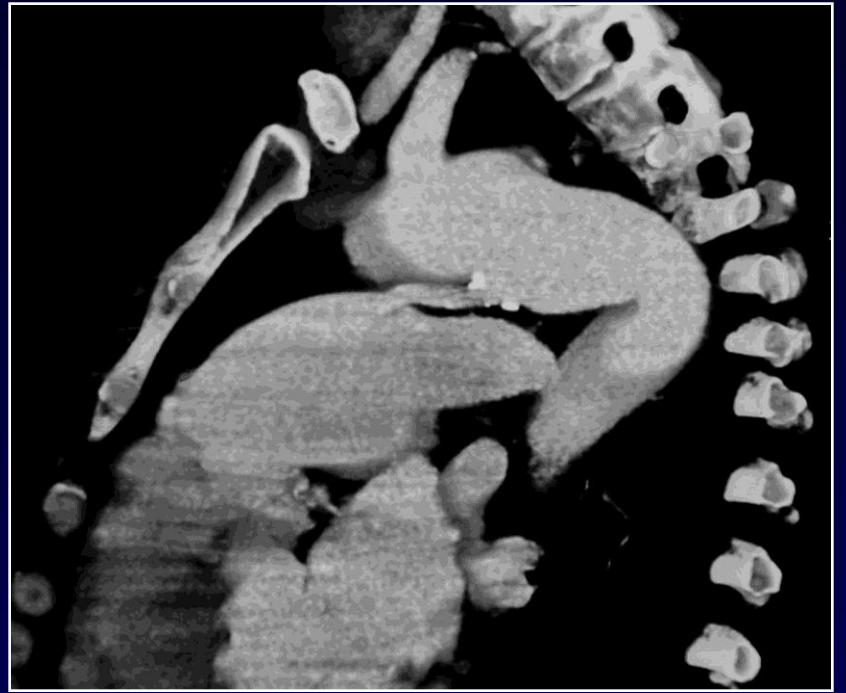
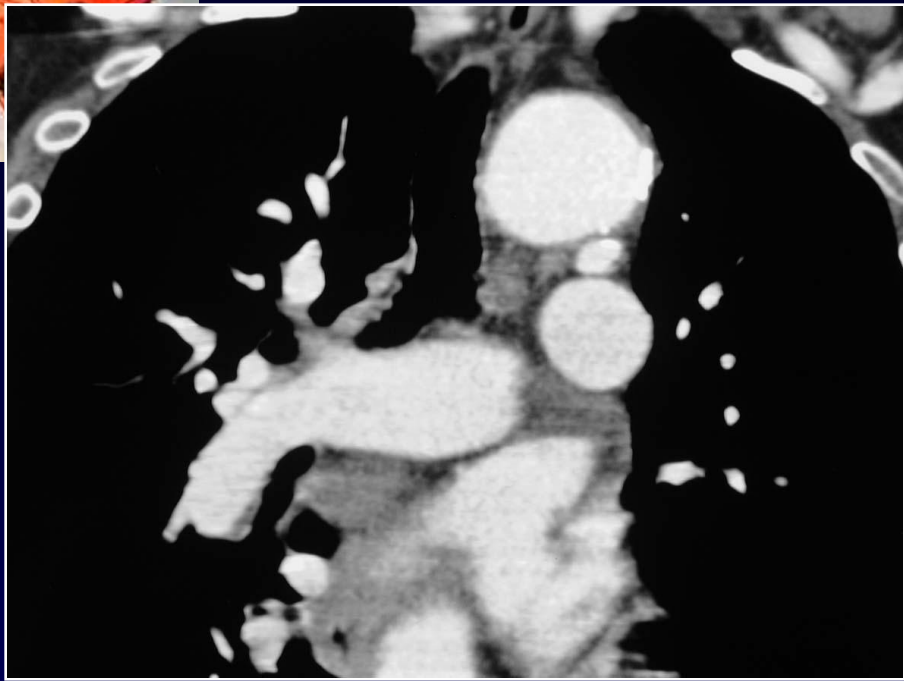
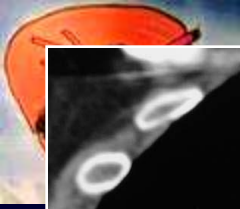

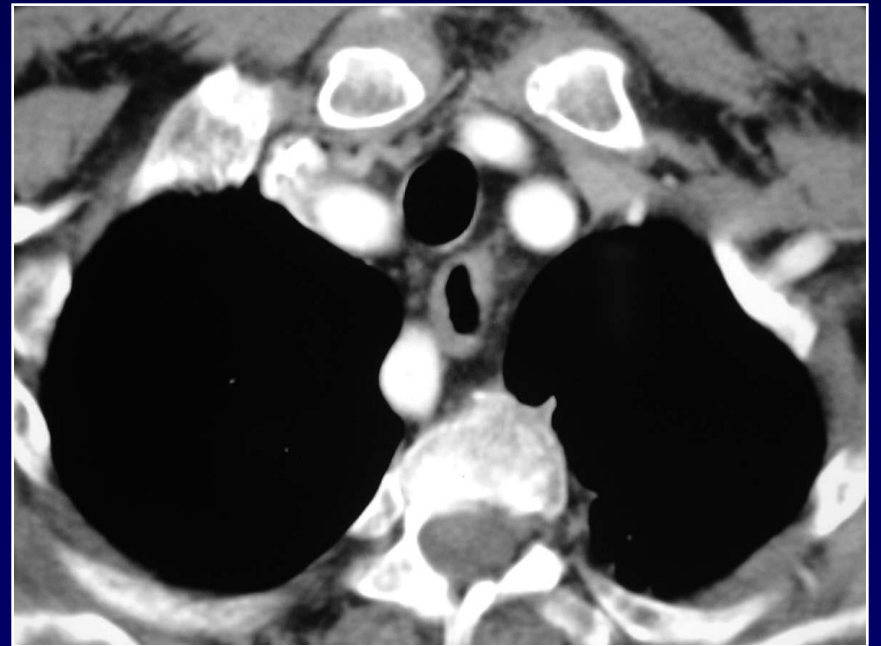
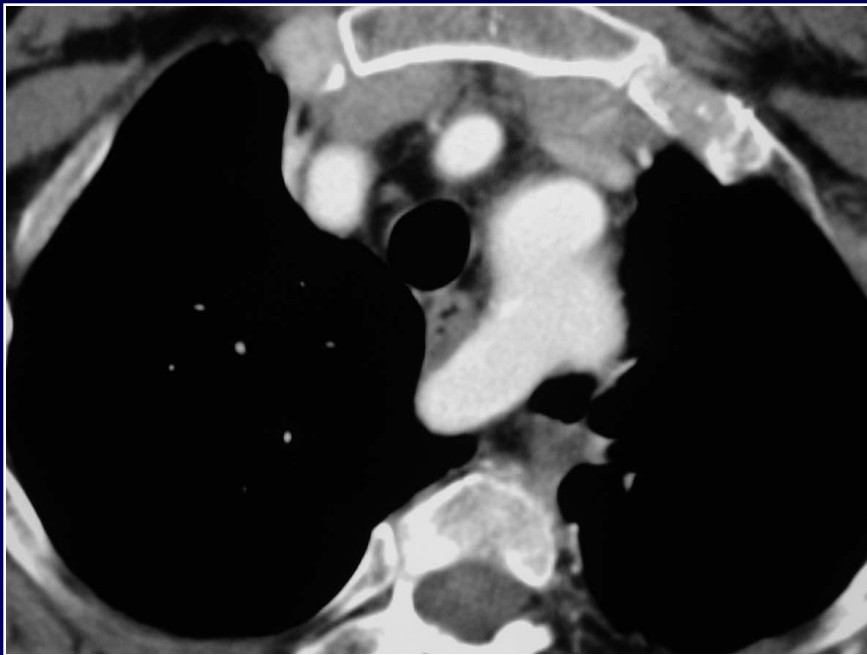
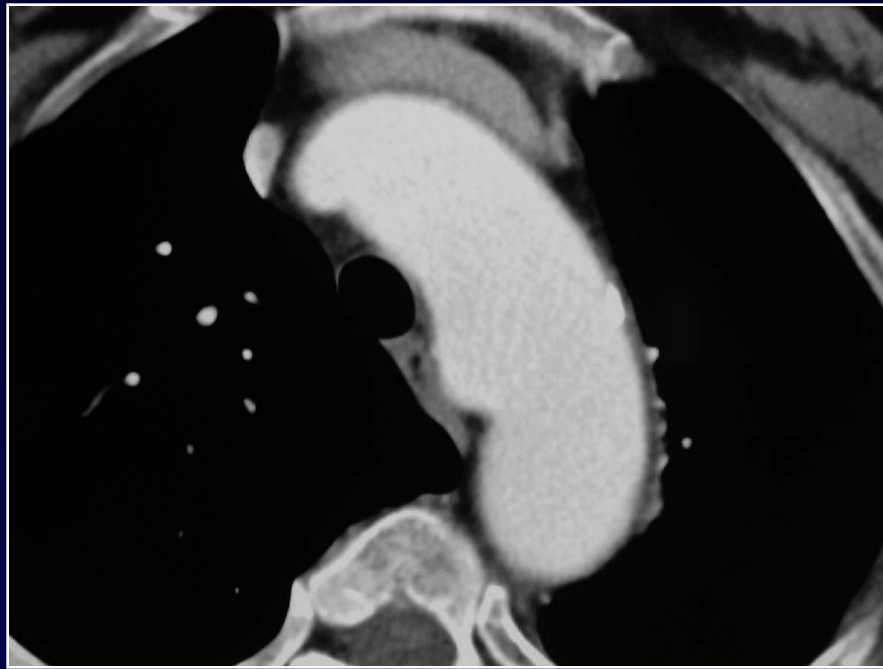
J. GIRON

Homme de 81 ans

Découverte fortuite

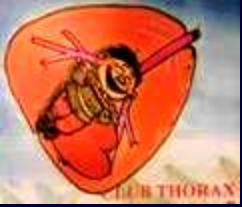







Diagnostic ?



Persistance du canal artériel

(41 mm de pression moyenne dans l'AP)

Artère sous clavière droite rétro-oesophagienne